

Lower Four One-Piece Implant Overdenture

Small diameter implants can do wonders for a lower full denture. This case provides a great example.

RLang

Posted: 9/2/2010

Post: 1 of 11

A 76-year-old patient presented with an old poor fitting denture, deficient ridge, and not a lot of attached gingiva. She desired more retention with her lower denture. She elected a more economical treatment plan of four one-piece 3x12 Biohorizons implants.

Fig. 1: Preop lower mandible

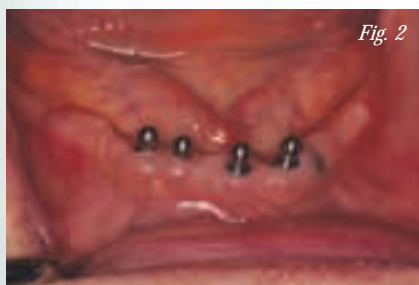
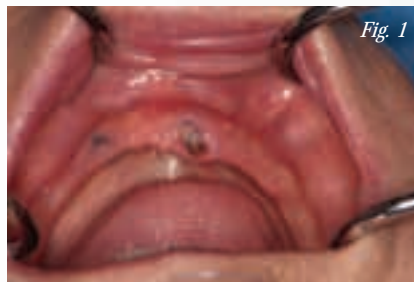
Fig. 2

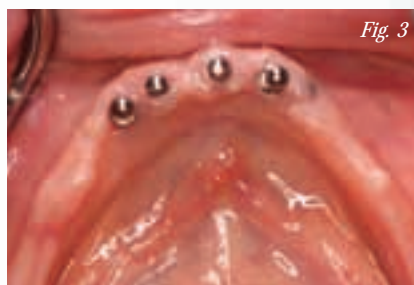

Fig. 3

Looking for more overdenture cases? Why not check out these message boards on Dentaltown.com:

Implant Placement for Lower Overdenture Using Cone Beam for Treatment Planning

Search: *Implant Placement for Lower*

Staged Mandibular Implant Overdenture Treatment.

Search: *Staged Mandibular*

Simple Lower Overdenture

Search: *Simple Lower Overdenture*

or... Scan this tag with your mobile phone to view this message board.




Fig. 4



Fig. 5



Fig. 6

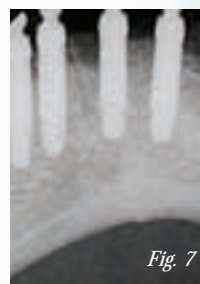


Fig. 7

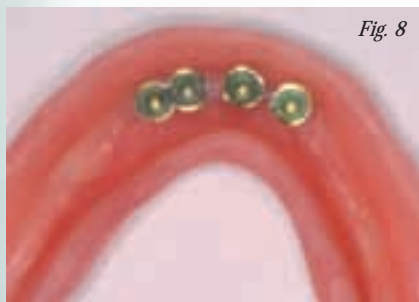

Fig. 8

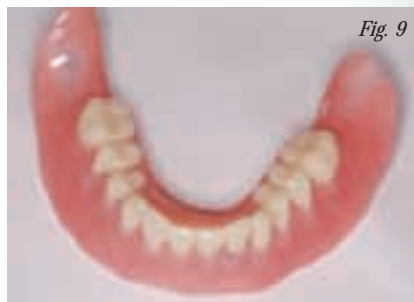

Fig. 9

Fig. 2: Postop three months healing

Fig. 3: Postop mandible three months healing

Figs. 4-5: Positioning pins

Figs. 6-7: Final X-rays

Fig. 8: New denture with attachments

Fig. 9: Lower denture

continued on page 30

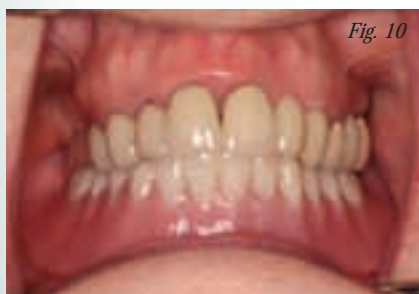

Fig. 10

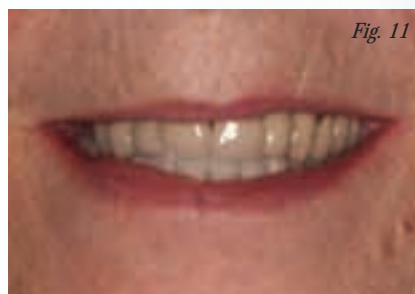

Fig. 11

Fig. 10: Final retracted

Fig. 11: Final smile.

This was a great indication for use of these implants. The 3mm one-piece implants were narrow enough to use on her ridge and much stronger than a mini. The lab fees are less because you do not have to buy an additional attachment to place in the implant. The disadvantage of this is if an attachment wears you cannot easily fix it, replacing the implant is needed. Another disadvantage is that during the healing stage the patient must be very careful to not function on the implants. Her old lower was relined with a soft liner and the implant areas were aggressively ground out. The ridge was so narrow I had to perform an alveoplasty to obtain enough width to place these implants. Due to her age and delicate bite, this treatment should serve her well. If she had a stronger bite I would be concerned long term as it is opposing upper crowned teeth. Thanks for any comments. ■

Huntington
Welcome.

IT'S NOT HOW WELL THEY'LL WORK FOR US. IT'S HOW WELL THEY'LL WORK FOR YOU.

The Huntington Investment Company is proud to welcome the newest members of our team, Steve McElroy and Ben Forgrave, Financial Advisors. Stop by the Dublin office located at 6744 Avery-Muirfield Drive, or call Steve and Ben at 614-480-5899 and find out how they can help you.

Investment and Insurance products and services are offered by the Huntington Investment Company, member FINRA/SIPC, a Registered Investment Advisor and a wholly owned subsidiary of Huntington Bancshares, Inc.
NOT A DEPOSIT • NOT FDIC INSURED • NOT GUARANTEED BY THE BANK • MAY LOSE VALUE • NOT INSURED BY ANY FEDERAL GOVERNMENT AGENCY
 ® and Huntington® are federally registered service marks of Huntington Bancshares Incorporated. Huntington® Welcome.™ is a service mark of Huntington Bancshares Incorporated. ©2010 Huntington Bancshares Incorporated.

FREE FACTS, circle 41 on card

Jordan "skibum" Pilling I bet she is so happy. I
 Posted: 9/2/2010 recommend this treatment
 Post: 2 of 11 to many of my patients but
 often have difficulty with
 case acceptance for the overdenture. Is there any reason
 why you placed them all so close and anterior instead
 of placing two a little further back? I am assuming that
 is just where you had the bone to do it. ■

utdental What advantage does
 Posted: 9/2/2010 the patient receive by doing
 Post: 3 of 11 four instead of just two –
 especially if they are all ante-
 rior to the mental foramen like these? The only advan-
 tage I see is this sets them up to transition to a fixed
 appliance in the future with a few more implants. Is
 there really a big change in retention when they are
 this close? ■

sensei These implants are one-
 Posted: 9/2/2010 piece so there is no transition-
 Post: 4 of 11 ing to fixed. I have the same
 questions though. Would it
 have been almost as cost effective to place 2x3.0

continued on page 32

implants with locators? Wouldn't this make it possible to change the abutments later if they wear or convert to a fixed/removable hybrid? I do see the advantage of the case being overengineered. If you happen to lose one, the case is still successful. I took an IMTEC course and they really pushed the idea of placing four to five minis so the case is not a flop if one fails. Definitely a nice case. I'm sure your patient is very happy. ■

mandm_sudz

Posted: 9/2/2010

Post: 6 of 11

You could and should have placed the distal-most implants way more distal, or just placed three implants instead of four tightly spaced ones. Two regular implants with locators would have done the trick and are upgradeable, as someone correctly mentioned earlier. In my opinion, if you are going to place minis, true minis would be better. These are 3mm implants and the case should be flapped to visualize bone architecture so they can be correctly placed. ■

RLang

Posted: 9/2/2010

Posts: 8,10 & 11 of 11

Thanks for your comments.

Jordan, the mandible was very thin and after alveoloplasty this was all I could place. I did want to place two further back but was unable to. There are three reasons to place four implants. 1. The case is more retentive even though the ap spreads is not ideal. 2. Implants retain bone and this will keep the anterior ridge from further atrophy especially against the upper natural crowned teeth. 3. This case will not fail if one implant is lost, it is overengineered.

These are one-piece implants and cannot be transitioned over. This is a dead end case and all that can be done without extensive bone grafting.

[Posted: 9/2/2010]

Martin, This case was flapped and the ridge-reduced to allow for placement of 3mm diameter implants. I could not place anything wider. There was not a lot to work with distal to these implants. I could have done three I guess, but did want to put in four and they did a little close. The case is very retentive and the patient was very pleased. It was not ideal and the reason I posted this case for discussion.

[Posted: 9/2/2010]

Sensei, There are no other plans for this case. Using two 3mm implants with locators is another way to go. The problem with the one-piece implants is they can wear and not be swapped out. But the advantage is they are much stronger. I have done other cases and placed two so it could be changed in the future or added to. This treatment was a simple economical solution to this patient's problem, however not so flashy. ■

Negotiating a Lease?

Don't let the landlord take advantage of you.

“ I cannot say enough good things about you. ”

*-Dr. Scott Goldstein,
Coram, NY*

To level the playing field, simply call toll-free or visit georgevaille.com/dt/

GEORGEVAILL
DENTAL OFFICE LEASE NEGOTIATIONS
800-340-2701



Find it online at www.dentaltown.com

One-Piece Implant Overdenture

Search